



Original research

A Workflow Change in Anterior Approach Total Hip Arthroplasty Leads to Improved Accuracy of Biomechanical Reconstruction Without Increased Risk of Complications

Stephanie V. Kaszuba, MD ^{a, b}, Kyle M. Behrens, MD ^{a, b}, Chad B. Anderson, PA-C ^{b, c, d}, Alexander C. Gordon, MD ^{b, c, d, *}

^a Chicago Medical School, Rosalind Franklin University of Medicine and Science, North Chicago, IL, USA

^b Department of Orthopedic Surgery, Illinois Bone & Joint Institute, Morton Grove, IL, USA

^c Department of Orthopedic Surgery, Advocate Lutheran General Hospital, Park Ridge, IL, USA

^d Department of Orthopedic Surgery, NorthShore Skokie Hospital, Skokie, IL, USA

ARTICLE INFO

Article history:

Received 18 March 2021

Received in revised form

26 May 2021

Accepted 14 June 2021

Available online xxx

Keywords:

Total hip arthroplasty

Femur first

Hip biomechanics

Outcomes

ABSTRACT

Background: During anterior approach total hip arthroplasty (THA), the femur may be an impediment for acetabular access, pushing reamers proximally and consequently altering the hip center. In an effort to address this, the senior author changed the surgical workflow from acetabulum first (AF) to femur first (FF). The objective of this study was to compare the precision of biomechanical hip reconstruction and clinical outcomes between the FF and AF techniques.

Methods: This is a retrospective, case-control study of 267 anterior THAs (132 AF and 135 FF). A normal, contralateral hip was used to determine the native biomechanical parameters. Using a calibrated software program, radiographic measurements were performed to calculate the hip center position, femoral offset, global offset, and leg length of the operative and native hips using 2-week postoperative anteroposterior pelvis radiographs. Demographics, operative information, hemoglobin change, and complication data were obtained. Functional outcomes were assessed with the Hip Dysfunction and Osteoarthritis Outcome Score for Joint Replacement survey at 1 year postoperatively.

Results: The groups exhibited similar demographic characteristics. The FF group demonstrated significantly more accurate and more precise reconstruction of horizontal and vertical hip centers, femoral offset, and leg length. There was no significant difference in operative time, hemoglobin change, complication rate, or Hip Disability and Osteoarthritis Outcome Score, Joint Replacement scores between groups.

Conclusions: The FF technique allowed for more accurate and precise reconstruction of the hip center, leg length, and offset in THA than the AF workflow. Furthermore, the FF approach demonstrated no significant differences in complication rate or blood loss, nor in clinical outcomes.

Level of Evidence: Therapeutic Study Level III.

© 2021 The Authors. Published by Elsevier Inc. on behalf of The American Association of Hip and Knee Surgeons. This is an open access article under the CC BY-NC-ND license (<http://creativecommons.org/licenses/by-nc-nd/4.0/>).

Introduction

Total hip arthroplasty (THA) is a proven, successful operation for reducing pain and restoring function in patients with end-stage coxarthrosis. Accurate reconstruction of hip biomechanics,

including the center of rotation, offset, and leg length, is necessary to optimize soft-tissue tension, muscle function, hip stability, and clinical outcomes [1–7]. Abnormal mechanics can lead to instability, pain, increased wear of the prosthetic components, decreased range of motion, and gait irregularities, such as a persistent limp [4,8–13].

The anterior approach total hip replacement has gained popularity, with some purported advantages being improved stability and function due to soft-tissue preservation. Additional benefits include improved patient-reported pain and functional outcomes, decreased postoperative length of stay, reduced dislocation, decreased postoperative narcotic requirements, and a greater

* Corresponding author. Department of Orthopedic Surgery, Illinois Bone & Joint Institute, 9000 Waukegan Road, Suite 200, Morton Grove, IL 60053, USA. Tel.: +1 847-375-3000.

E-mail address: agordon@ibji.com

percentage of acetabular cups placed in the “safe” zone of alignment due to the use of intraoperative fluoroscopy when compared to the posterior approach [14–19]. The workflow of the operation often involves acetabular preparation and implantation subsequent to the femoral neck osteotomy. In some cases, the remaining femoral neck combined with posterior soft-tissue contracture will lead to suboptimal exposure by blocking the distal aspect of the acetabulum. If reaming and acetabular component implantation are carried out under these circumstances, there is a risk of displacing the hip center. In an assessment of 894 THA cases performed with a lateral, posterior, and direct anterior approach, Benson et al. found that the hip center of rotation was commonly displaced in the medial, superior, and posterior directions [12]. Posterior displacement was greater with the anterior approach. In addition, medial displacement of the hip center also resulted in increased superior and posterior displacement across all cases [12]. Once the acetabular cup is implanted, the surgeon must reconstruct leg length and offset using the femoral component and modular femoral head. If the hip center is in a nonanatomic position, this leads to technical challenges in accurately reconstructing these parameters. Thus, accurate restoration of hip biomechanics during THA is critical to optimize patient functionality and decrease the risk of unsatisfactory clinical outcomes but can pose an intraoperative challenge.

In an effort to optimally prepare and implant the acetabulum, the senior surgeon began using a “femur-first” (FF) workflow. Preparing the femur first allows the femoral releases and calcar planing to assist in femoral retraction, potentially improving exposure during acetabular preparation. A concern with the FF methodology is that the preparation of the femur early in the case may lead to increased blood loss, which has been previously studied [20]. Many of the prior studies on the FF technique investigate the effects of combined anteversion on impingement, dislocation, and musculoskeletal loading, with or without the use of computer navigation [21–27]. In addition, many of these studies used posterior, posterolateral, and anterolateral approaches to the hip. To our knowledge, there have been little data investigating the FF technique through a direct anterior approach.

The purpose of this study is to evaluate the direct anterior approach THA using a FF technique in comparison to the traditional acetabulum-first (AF) method, without the application of combined anteversion principles or use of computer navigation. In particular, we aimed to answer the following questions: (1) Does the FF technique improve the radiographic accuracy of biomechanical hip reconstruction, including the center of rotation, femoral offset, global offset, and leg length, compared with the AF approach? (2) Do the 2 approaches vary in postoperative patient-reported outcomes? (3) Is this change in workflow associated with variation in blood loss, operative time, or complication rate? We believe this study will provide evidence for a change in workflow to improve biomechanics and postoperative outcomes for patients undergoing THA through a direct anterior approach.

Material and methods

Institutional review board approval was obtained before initiating the investigation. In this two-group, retrospective cohort study, we reviewed the radiographs and charts of patients who underwent primary direct anterior THA performed by one fellowship-trained orthopedic surgeon between February 2017 and September 2019. During this time, the surgeon performed 695 anterior THA procedures. Surgical sites consisted of 2 hospitals and 2 ambulatory surgical centers. The AF technique was used in earlier patients, with all cases switching to FF workflow on July 1, 2018. To account for a potential learning curve, FF patients whose surgeries

occurred before September 1, 2018, were excluded. A preliminary radiographic analysis was conducted on all cases, using the status of the contralateral hip as inclusion criteria. A normal, nonarthritic contralateral hip was necessary to discern the native state of the hip center, offset, and radiographic limb length which were determined to be the targets for the arthroplasty. Cases with a contralateral THA, advanced degenerative changes, malrotated radiograph, or indiscernible radiographic teardrops were excluded, resulting in 267 cases (132 AF and 135 FF) available for analysis. In all cases, hip arthroplasty was performed after digital templating, and fluoroscopic overlay was used intraoperatively for assessment of component positioning.

Surgical technique

All procedures were performed on the HANA orthopedic table (Mizuho Osi, Union City, CA). The surgical approach from skin incision to femoral neck osteotomy was performed in an identical fashion in both study groups. In the AF group, the operation proceeded with acetabular preparation and implantation subsequent to the osteotomy. In the FF group, the femur was exposed, and a majority of the femoral preparation was performed. The only difference between groups was the order of the steps. Acetabular exposure and preparation were similar in each group. The fluoroscope was positioned over the center of the pelvis at the level of the acetabula. Adjustments were made to the C-Arm position until the fluoroscopic image matched the preoperative anteroposterior pelvis radiograph. The image was centered on the acetabulum to guide the reaming angle and depth. Reaming typically began at 6 mm lower than the planned acetabular component size and progressed in 2-mm and 1-mm increments until the appropriate size had been reached. Fluoroscopy and direct vision were used to determine appropriate component positioning during implantation. All cups were impacted with a 1-mm under-ream, and the use of screws was determined by the surgeon's subjective assessment of cup stability. Intraoperative biomechanical assessment was performed with the fluoroscopic overlay technique, using the normal contralateral hip as the guide, without enabling software or navigation.

Radiographic examination was performed at each patient's follow-up appointments. Postoperatively, the 2-week anteroposterior pelvis radiographs for all 267 cases were calibrated and measured by 2 trained, blinded evaluators with a commercially available digital templating software program (OrthoView, Plymouth, MI). Calibration markers, along with a sphere tool, were positioned to fit the contour of the prosthetic femoral head component on the digital radiograph. From the operative report, the known size of the prosthetic head was entered into the templating software, permitting the system to calibrate the radiograph and correct for magnification error. The target for the measurements on the operative side was to match those of the contralateral native hip. The variables calculated on the operative and native hips were vertical and horizontal components of the hip center, femoral offset, global offset, and radiographic leg length. The measurement technique is depicted in [Figure 1](#). In short, a trans-teardrop line (TTL) was drawn across the pelvis and was used to anchor the measurements. The vertical hip center was measured via a perpendicular line from the TTL to the hip rotation center. A line perpendicular to the TTL through the medial aspect of the teardrop was also drawn. The horizontal hip center was measured as the distance from this medial reference to the hip rotation center. Femoral offset was measured as the distance between the hip rotation center and the anatomic axis of the femur. Global offset was calculated as the sum of the horizontal component of the hip center and the femoral offset. Radiographic leg length was

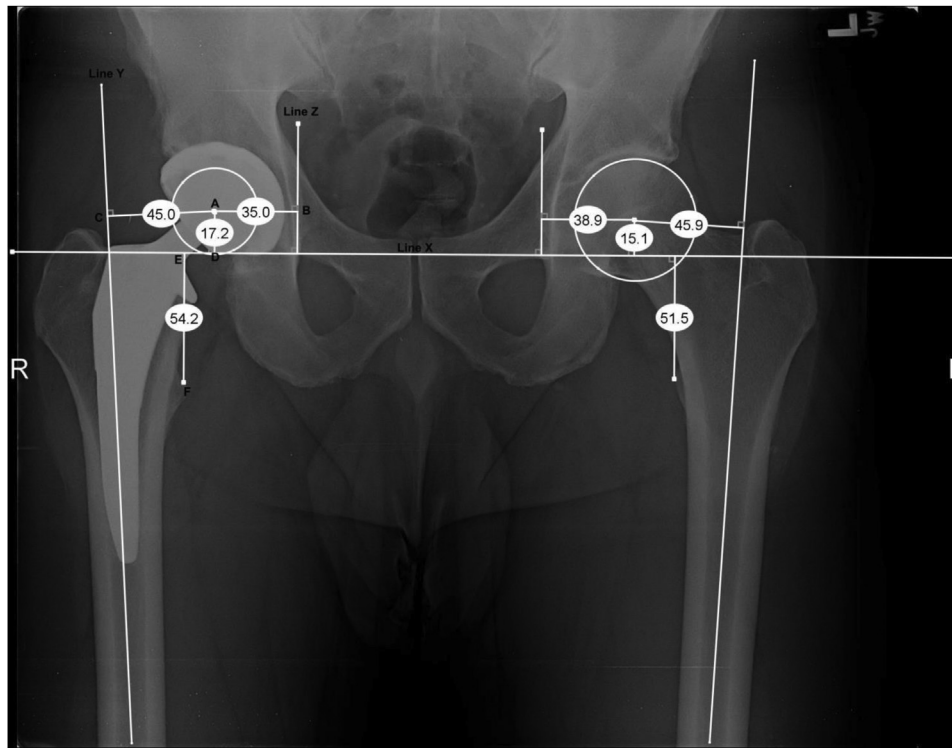


Figure 1. Radiographic Measurements of Hip Biomechanics. Line X represents the trans-teardrop line, intersecting the inferior portion of the teardrops. Line Z is perpendicular to line X at the medial aspect of the teardrop. Line Y runs through the anatomic axis of the femur. Point A is the center of the femoral head. Line AB is the horizontal component of the hip center of rotation. Line AD is the vertical component of the hip center of rotation. Line AC is the femoral offset. Lines AB + AC is the global offset. Line EF is the radiographic limb length.

measured as the distance between the TTL and the most prominent aspect of the lesser trochanter [28–30]. Patients with greater than 5 mm difference between native and hip arthroplasty measurements were considered radiographic outliers.

Data collected from the electronic health records included patient demographics, operative information, preoperative and postoperative hemoglobin levels, complications, and postoperative radiographs. A complication was defined as a fracture, femoral perforation, dislocation, infection with return to the operating room for wound irrigation and debridement (I&D) or revision, transfusion, and aseptic arthroplasty revision. Patients were followed up for a minimum of 1 year after their procedure. Adverse events occurring within the hospital or surgical center, or within 1 year postoperatively, were recorded. Patient-reported outcomes were collected using the Hip Disability and Osteoarthritis Outcome Score, Joint Replacement (HOOS, JR) survey [31] administered at follow-up appointments. The HOOS, JR survey includes 6 questions evaluating hip pain and daily function. An interval score of 100 represents ideal hip health, while 0 indicates complete hip disability. Groups were compared using a *t* test for continuous, normally distributed data, a Mann-Whitney U test for nonparametric data, and a χ^2 test for categorical data. A two-tailed *P* value of ≤ 0.05 was considered statistically significant. Analyses were performed using the SPSS software, version 27 (IBM Corp., Armonk, NY).

Results

Of the 695 anterior approach THA procedures performed by the surgeon during the designated study time period, 267 (135 FF and 132 AF) patients met the inclusion criteria of a primary THA with minimal degenerative changes in the contralateral native hip and

an adequate 2-week anteroposterior pelvis radiograph. Patient characteristics were similar in the FF and AF groups, including age (67.16 years in FF vs 67.39 in AF, $P = .850$), gender (38.5% male vs 35.6%, $P = .622$), body mass index (28.5 vs 28.17, $P = .596$), and American Society of Anesthesiologists Physical Status Classification (2.23 vs 2.19, $P = .453$). Subject demographics are summarized in Table 1. Intraoperatively, there were no significant differences in surgical duration (78.76 vs 77.78 minutes, $P = .473$), stem implant received (50.4% Actis, 37.8% Corail, 11.8% other vs 43.9% Actis, 37.9% Corail, 18.2% other, $P = .100$), and proportion of cases using IV tranexamic acid (86.7% vs 81.1%, $P = .213$) between the FF and AF groups, respectively. In addition, the decrease in hemoglobin from the preoperative to postoperative day 1 measurement was comparable (18.02% in FF vs 18.57% in AF, $P = .478$), as was the mean duration of hospital stay (1.78 vs 2.0 days, $P = .191$) (Table 2).

There were 2 complications in the FF group and 5 in the AF cohort ($P = .086$). Among the FF complications, there was one infection resulting in septic loosening of the acetabular component, which was treated with a revision. The other FF patient experienced

Table 1
Subject demographics (N = 267).

Characteristic	FF (n = 135)	AF (n = 132)	<i>P</i> value
Age at surgery	67.16 ± 9.8 ^a	67.39 ± 10.1	.850
Gender			.622
Male	52 (38.5) ^b	47 (35.6)	
Female	83 (61.5)	85 (64.4)	
Body Mass Index (Kg/m ²)	28.50 ± 5.5	28.17 ± 4.9	.596
ASA class	2.23 ± .52	2.19 ± .51	.453

ASA, American Society of Anesthesiologists Physical Status Classification.

^a Data are expressed as mean ± standard deviation.

^b Data are expressed as number (percent).

an acute kidney injury and symptomatic hyponatremia during the postoperative recovery course. There were 3 infections within the AF group. In one case, a patient developed a subcutaneous abscess and underwent I&D, as well as exchange of the polyethylene liner and femoral head 3 weeks after initial THA. Another patient experienced wound dehiscence with subsequent cellulitis and was treated with antibiotics and I&D of a seroma cavity 2 months after THA, after which the incision healed completely. The third case did not exhibit gross evidence of infection; however, the patient did experience superficial wound necrosis and returned to the operating room at 5 weeks for I&D and wound closure. One AF case had an intraoperative calcar fracture, which was fixed with 2 cable wires. An AF patient with substantial femoral anteversion experienced femoral perforation intraoperatively, which was addressed by removing some of the greater trochanter to allow for better femoral access and using a longer prosthesis than originally planned for to bypass the perforation and achieve stability. Finally, there were 2 AF cases with medical complications during the postoperative course, including deep vein thrombosis treated with rivaroxaban and a myocardial infarction treated with percutaneous coronary intervention. There were no instances of periprosthetic fracture, dislocation, aseptic revision, or need for transfusion in either group. Further comparison of the complications is presented in Table 2. We obtained complete 1-year clinical follow-up on 226 cases (85%) (109 AF and 117 FF). At 1 year after THA, patients reported similar outcomes on the HOOS, JR surveys with a mean score of 88.90 and 90.97 in the FF and AF groups, respectively ($P = .539$).

Hip biomechanics were assessed for the THA and contralateral native hips with measurements performed on 2-week postoperative radiographs for all 267 cases (Table 3). The absolute difference (|native hip - THA hip|) for the horizontal and vertical components of the center of rotation significantly varied between the FF and AF groups. The mean difference in the horizontal

component of the hip center was 2.17 mm in the FF group and 2.39 mm in the AF group ($P < .001$). Only 7.41% of FF cases were outliers (ie, exhibited ≥ 5 mm difference between native and THA hips), as opposed to 18.18% of AF cases ($P = .008$). Similarly, the difference in the vertical component of the hip center was 2.16 mm in the FF group and 3.23 mm in the AF group ($P < .001$) with 11.11% and 20.45% of outliers, respectively ($P = .036$). Significant variation was also found in femoral offset, with the FF cohort exhibiting a mean difference of 1.88 mm between the native and THA hips, while the AF group averaged 2.72 mm ($P = .001$). In regard to femoral offset, 14.39% of the AF cases were outliers, in contrast to 8.15% of FF cases ($P = .106$). Although the mean difference in global offset was not statistically significant, with 1.85 mm in FF and 2.19 mm in AF ($P = .828$), the number of outliers was notable at 3.70% vs 9.85%, respectively ($P = .045$). Finally, the average leg length discrepancy was 2.26 mm in the FF cohort and 3.15 mm in the AF group ($P = .026$), with 8.89% and 18.94% of outliers, respectively ($P = .017$).

Discussion

The primary purpose of this study was to evaluate the biomechanical reconstruction of direct anterior approach THA using the FF technique in comparison to AF workflow. To our knowledge, this is the first study directly comparing radiographic and clinical outcomes of different workflow techniques in exclusively anterior approach hip arthroplasty. The results of our review indicate that the FF technique improves the accuracy and precision of several hip biomechanical parameters. In particular, when comparing the THA to the contralateral native hip radiographically, the FF group demonstrated significantly more accurate horizontal and vertical hip center of rotation positions ($\Delta 2.17$ and 2.16 mm in FF vs 3.25 and 3.23 mm in AF, respectively), femoral offset ($\Delta 1.88$ vs 2.72 mm), and limb length ($\Delta 2.26$ vs 3.15 mm). In addition, the FF cohort also exhibited a more precise horizontal and vertical hip center of rotation (7.41% and 11.11% outliers in FF vs 18.18% and 20.45% in AF, respectively), global offset (3.70% vs 9.85% outliers), and leg length (8.89% vs 18.94% outliers).

There are various limitations to this study. Preferably, an investigation examining 2 techniques would be prospective and randomized. As this was a retrospective, nonrandomized study, there may have been limited ability to control for potential bias. Despite the lack of true randomization, there were no significant differences in patient demographics or surgical equipment and implants used. In addition, the follow-up protocol remained unchanged throughout the study period. A single-surgeon study also limits generalizability of results yet offers the benefit of consistent operative techniques, as well as uniform preoperative and postoperative protocols. There was no formal interobserver reliability test between the radiograph evaluators; however, both evaluators

Table 2
Operative and postoperative data (N = 267).

Characteristic	FF (n = 135)	AF (n = 132)	P value
Operation time (min) ^a	78.76 ± 10.4 ^b	77.78 ± 11.6	.473
Length of hospital stay (d)	1.78 ± 1.7	2.0 ± 1.0	.191
Stem type ^c			.100
Actis	68 (50.4) ^d	58 (43.9)	
Corail	51 (37.8)	50 (37.9)	
C-Stem	10 (7.4)	19 (14.4)	
Summit	1 (0.7)	5 (3.8)	
Accolade II	5 (3.7)	0 (0)	
Tranexamic acid usage			.213
IV	117 (86.7)	107 (81.1)	
Topical	18 (13.3)	25 (18.9)	
Δ Hemoglobin [preop - postop]	2.50 ± 0.8	2.57 ± 0.9	.577
Percent decrease in Hgb	18.02 ± 5.6	18.57 ± 6.1	.478
Complications			.086
Intraoperative calcar fracture	0	1	.311
Intraoperative femoral perforation	0	1	.311
Periprosthetic fracture	0	0	—
Dislocation	0	0	—
Transfusion	0	0	—
Infection	1	3	.303
Aseptic revision ^e	0	0	—
Medical complication ^f	1	2	.549
1-year HOOS, JR outcomes ^g	88.90 ± 13.9	90.97 ± 10.9	.539

^a First cut to close.

^b Data are expressed as mean ± standard deviation.

^c Actis, Corail, C-Stem, Summit (DePuy Synthes, Warsaw, IN); Accolade II (Stryker Inc, Mahwah, NJ).

^d Data are expressed as number (percent).

^e Revision for causes other than treatment of infection.

^f Includes 1 acute kidney injury in the FF group; 1 deep vein thrombosis and 1 myocardial infarction during the postoperative course in the AF group.

^g FF (n = 117), AF (n = 109).

Table 3
Hip biomechanics (N = 267).

Radiographic measurements	FF (n = 135)	AF (n = 132)	P value
Δ Horizontal hip center [native - THA] (mm)	2.17 ± 1.9 ^a	3.25 ± 2.4	<.001
Number of outliers ≥ 5 mm	10 (7.41) ^b	24 (18.18)	.008
Δ Vertical hip center (mm)	2.16 ± 2.0	3.23 ± 2.3	<.001
Number of outliers ≥ 5 mm	15 (11.11)	27 (20.45)	.036
Δ Femoral offset (mm)	1.88 ± 1.9	2.72 ± 2.2	.001
Number of outliers ≥ 5 mm	11 (8.15)	19 (14.39)	.106
Δ Global offset (mm)	1.85 ± 1.4	2.19 ± 2.1	.828
Number of outliers ≥ 5 mm	5 (3.70)	13 (9.85)	.045
Δ Leg length (mm)	2.26 ± 1.8	3.15 ± 2.9	.026
Number of outliers ≥ 5 mm	12 (8.89)	25 (18.94)	.017

^a Data are expressed as mean ± standard deviation.

^b Data are expressed as number (percent).

reviewed each radiograph in the study and were in agreement regarding biomechanical measurements and radiographic findings. Another limitation is that the hip center of rotation was evaluated only with anteroposterior radiographs of the pelvis and was not further assessed in the sagittal plane or 3-dimensionally with CT-guided imaging. Benson et al. found that the direct anterior approach is associated with an increased posterior displacement of the hip center of rotation compared with lateral and posterior approaches, a measurement we were unable to obtain [12]. Future directions of this study could explore the hip center of rotation parameters in a 3-dimensional orientation.

Despite these limitations, we feel that this investigation was able to answer our research questions and provide further insight into the FF technique. Restoration of hip biomechanics is an important factor while performing THA to ensure a successful patient outcome and survivorship of the prosthetic joint. The importance of restoring the hip center of rotation, femoral offset, global offset, and limb length is individually well documented. Durand-Hill et al. discuss errors in recreating the hip center: Posterior displacement generates anteroposterior laxity, and medial displacement increases medial-lateral laxity, both of which increase risk for dislocation [13]. The principal study question we sought to address was whether FF workflow would improve biomechanical hip reconstruction in comparison to the traditional AF workflow. Previous studies have reported increased femoral offset to result in leg lengthening, which can lead to a perceived leg length discrepancy and impaired function [1]. In a systematic review, De Fine et al. found a statistically significant correlation between femoral offset restoration and reduction of conventional ultrahigh-molecular-weight polyethylene wear [5]. Femoral offset within 5 mm restoration has also been shown to improve abductor muscle strength, decrease walking aid use [2,6], and prevent knee adduction movement [7]. Similarly, global offset and leg length accuracy within 5 mm of the nonoperative side improves walking speed and increases hip range of motion [4]. Several patient-reported outcome studies have shown improved functional outcome scores and daily quality of life. Innmann et al. demonstrated that patients undergoing THA who had accurate hip offset reconstruction and balanced leg length had significantly higher Harris Hip Scores ($P = .029$) [3]. In addition, there were worse Western Ontario and McMaster Universities Osteoarthritis Index (WOMAC) scores in patients that had undercorrected femoral offset [1,2]. We found that the FF technique significantly improves the accuracy of the hip center of rotation, femoral offset, and leg length. In addition, the number of outliers, or cases that exhibited more than 5-mm difference between the THA and native hips, was noted for each category of measurements. This cutoff was selected as prior studies suggest that a difference of greater than 5 mm affects patient outcomes and joint survivorship [2,12]. Our study reveals significantly fewer outliers among the FF group in regard to the horizontal and vertical hip center, global offset, and leg length discrepancy.

Currently, there is limited information on how patients report their outcomes after the FF technique. The second question we set out to answer was whether the FF and AF techniques resulted in similar patient-reported outcomes. We used HOOS, JR scores because of the survey's straightforwardness and our practice's existing use of the survey for quality reporting. Our results suggest that a surgeon can expect similar short-term outcomes with the FF technique as with AF workflow.

The third aim of our study was to assess intraoperative and postoperative variables of the FF technique, including operative time, blood loss, and complication rate. This information is critical for surgeons because it provides information as to whether a certain technique carries any additional risk for the patient. Our data indicate that for an experienced surgeon, the surgical duration

does not change with the FF technique. We were interested in examining the change in preoperative to postoperative hemoglobin, as the femur can be a source of appreciable blood loss. We considered that perhaps broaching the femur earlier in the procedure would contribute to greater blood loss. On the other hand, we also wondered whether early plugging of the femur would result in an earlier tamponade effect and decrease the bleeding time. Stevens et al. previously investigated blood loss differences between FF and AF preparation in THA with the use of intravenous tranexamic acid at induction [20]. In FF procedures, a femoral broach was placed into the canal soon after the femoral neck resection. Their results indicated a clinically and statistically insignificant reduction in total blood loss in the FF group of 39 mL ($P = .392$) [20]. While Stevens et al. plugged the femur with a well-fitted broach, the senior author found that this caused some restriction in acetabular access [20]. As an alternative, the surgical team created a plug using the mesh-sponge component of the femoral canal suction absorber from the Prep-IM Total Hip Preparation Kit (Smith and Nephew, Memphis, TN) soaked in a lidocaine and epinephrine mixture. We saw an 18.02% and 18.57% mean decrease in hemoglobin in the FF and AF groups, respectively. While we analyzed the change in hemoglobin as a marker for blood loss, our results were relatively consistent with the conclusions made by Stevens et al. [20] in that there is no statistically significant difference in blood loss between the 2 approaches.

Finally, the FF group exhibited fewer complications, although this was not statistically significant. The AF group had 3 occurrences of wound breakdown/infection; however, it is unlikely that the AF technique bears a greater risk of infection. The senior author used a subcuticular barbed suture for a brief period when these three AF cases were performed and noticed more instances of wound necrosis. Clinically, it may be worth noting that the FF group did not exhibit any intraoperative complications, such as calcar fractures or perforation. The extra step in the FF technique is a secondary femoral preparation after the acetabulum is completed. During the second preparation, there is oftentimes improved femoral exposure and a better ability to seat the broach at its appropriate level. The surgeon then has a third opportunity to finalize femoral size and depth after fluoroscopic analysis. It is possible that this progressive system of femoral preparation and implantation assisted in the low femoral complication rate noted in the FF group. However, further investigation is needed to determine whether this complication pattern is consistent.

Conclusions

Changing the THA workflow to FF rather than AF improves the accuracy and precision of several biomechanical parameters in a similar patient population. Furthermore, the FF technique demonstrated no significant differences in operative duration, blood loss, complications, or patient outcomes. This methodology appears to offer the surgeon a simple way to improve the quality of THA without increasing risk.

Conflicts of interest

The authors declare that they have no known competing financial interests or personal relationships that could have appeared to influence the work reported in this article.

Informed consent

Informed consent was waived from all patients for being included in this study.

References

- [1] Bolink SAAN, Lenguerrand E, Brunton LR, et al. The association of leg length and offset reconstruction after total hip arthroplasty with clinical outcomes. *Clin Biomech (Bristol, Avon)* 2019;68:89.
- [2] Mahmood SS, Mukka SS, Crnalic S, Wretenberg P, Sayed-Noor AS. Association between changes in global femoral offset after total hip arthroplasty and function, quality of life, and abductor muscle strength. A prospective cohort study of 222 patients. *Acta Orthop* 2016;87(1):36.
- [3] Innmann MM, Maier MW, Streit MR, et al. Additive influence of hip offset and leg length reconstruction on postoperative improvement in clinical outcome after total hip arthroplasty. *J Arthroplasty* 2018;33(1):156.
- [4] Renkawitz T, Weber T, Dullien S, et al. Leg length and offset differences above 5mm after total hip arthroplasty are associated with altered gait kinematics. *Gait Posture* 2016;49:196.
- [5] De Fine M, Romagnoli M, Toscano A, Bondi A, Nanni M, Zaffagnini S. Is there a role for femoral offset restoration during total hip arthroplasty? A systematic review. *Orthop Traumatol Surg Res* 2017;103(3):349.
- [6] Bjarnason JA, Reikeras O. Changes of center of rotation and femoral offset in total hip arthroplasty. *Ann Transl Med* 2015;3(22):355.
- [7] Stief F, van Drogenen S, Brenneis M, Tarhan T, Fey B, Meurer A. Influence of hip geometry reconstruction on frontal plane hip and knee joint moments during walking following primary total hip replacement. *J Arthroplasty* 2019;34(12):3106.
- [8] Weber M, Merle C, Nawabi DH, Dendorfer S, Grifka J, Renkawitz T. Inaccurate offset restoration in total hip arthroplasty results in reduced range of motion. *Sci Rep* 2020;10(1):13208.
- [9] Sakalkale DP, Sharkey PF, Eng K, Hozack WJ, Rothman RH. Effect of femoral component offset on polyethylene wear in total hip arthroplasty. *Clin Orthop Relat Res* 2001;388:125.
- [10] Komiyama K, Nakashima Y, Hirata M, Hara D, Kohno Y, Iwamoto Y. Does high hip center decrease range of motion in total hip arthroplasty? A computer simulation study. *J Arthroplasty* 2016;31(10):2342.
- [11] Fukushi JI, Kawano I, Motomura G, Hamai S, Kawaguchi KI, Nakashima Y. Does hip center location affect the recovery of abductor moment after total hip arthroplasty? *Orthop Traumatol Surg Res* 2018;104(8):1149.
- [12] Benson JR, Govindarajan M, Muir JM, Lamb IR, Sculco PK. Surgical approach and reaming depth influence the direction and magnitude of acetabular center of rotation changes during total hip arthroplasty. *Arthroplast Today* 2020;6(3):414.
- [13] Durand-Hill M, Henckel J, Satchithananda K, et al. Calculating the hip center of rotation using contralateral pelvic anatomy. *J Orthop Res* 2016;34(6):1077.
- [14] Nistor DV, Caterev S, Bolboacă SD, Cosma D, Lucaciu DOG, Todor A. Transitioning to the direct anterior approach in total hip arthroplasty. Is it a true muscle sparing approach when performed by a low volume hip replacement surgeon? *Int Orthop* 2017;41(11):2245.
- [15] Tamaki T, Oinuma K, Miura Y, Higashi H, Kaneyama R, Shiratsuchi H. Epidemiology of dislocation following direct anterior total hip arthroplasty: a minimum 5-year follow-up study. *J Arthroplasty* 2016;31(12):2886.
- [16] Hasegawa I, Wright AR, Andrews SN, Unebasami E, Nakasone CK. Hip offset and leg length equalization in direct anterior approach total hip arthroplasty without preoperative templating. *Hawaii J Health Soc Welf* 2019;78(11 Suppl 2):26.
- [17] Debbi EM, Rajae SS, Mayeda BF, Penenberg BL. Determining and achieving target limb length and offset in total hip arthroplasty using intraoperative digital radiography. *J Arthroplasty* 2020;35(3):779.
- [18] Higgins BT, Barlow DR, Heagerty NE, Lin TJ. Anterior vs. posterior approach for total hip arthroplasty, a systematic review and meta-analysis. *J Arthroplasty* 2015;30(3):419.
- [19] Galakatos GR. Direct anterior total hip arthroplasty. *Mo Med* 2018;115(6):537.
- [20] Stevens JM, Shiels S, Whitehouse M, Baker R. Preparing the femur before the acetabulum does not reduce total blood loss in primary total hip replacement. *J Orthop* 2019;16(4):353.
- [21] Renkawitz T, Haimerl M, Dohmen L, et al. Minimally invasive computer-navigated total hip arthroplasty, following the concept of femur first and combined anteversion: design of a blinded randomized controlled trial. *BMC Musculoskelet Disord* 2011;12:192.
- [22] Palit A, Williams MA, Turley GA, Renkawitz T, Weber M. Femur First navigation can reduce impingement severity compared to traditional free hand total hip arthroplasty. *Sci Rep* 2017;7(1):7238.
- [23] Weber TA, Dendorfer S, Grifka J, Verkerke GJ, Renkawitz T. Does computer-assisted femur first THR improve musculoskeletal loading conditions? *Biomed Res Int* 2015;2015:625317.
- [24] Loppini M, Longo UG, Caldarella E, Rocca AD, Denaro V, Grappiolo G. Femur first surgical technique: a smart non-computer-based procedure to achieve the combined anteversion in primary total hip arthroplasty. *BMC Musculoskelet Disord* 2017;18(1):331.
- [25] Nakashima Y, Hirata M, Akiyama M, et al. Combined anteversion technique reduced the dislocation in cementless total hip arthroplasty. *Int Orthop* 2014;38(1):27.
- [26] Renkawitz T, Weber M, Springorum HR, et al. Impingement-free range of movement, acetabular component cover and early clinical results comparing 'femur-first' navigation and 'conventional' minimally invasive total hip arthroplasty: a randomised controlled trial. *Bone Joint J* 2015;97-B(7):890.
- [27] Dorr LD, Malik A, Dastane M, Wan Z. Combined anteversion technique for total hip arthroplasty. *Clin Orthop Relat Res* 2009;467(1):119.
- [28] Austin DC, Dempsey BE, Kunkel ST, Torchia MT, Jevsevar DS. A comparison of radiographic leg-length and offset discrepancies between 2 intraoperative measurement techniques in anterior total hip arthroplasty. *Arthroplast Today* 2018;5(2):181.
- [29] Flecher X, Ollivier M, Argenson JN. Lower limb length and offset in total hip arthroplasty. *Orthop Traumatol Surg Res* 2016;102(1 Suppl):S9.
- [30] Takamatsu T, Shishido T, Takahashi Y, et al. Radiographic determination of hip rotation center and femoral offset in Japanese adults: a preliminary investigation toward the preoperative implications in total hip arthroplasty. *Biomed Res Int* 2015;2015:610763.
- [31] Lyman S. HOOS, JR. and KOOS, JR. Outcome surveys. Hospital of special surgery. <https://www.hss.edu/hoos-jr-koos-jr-outcomes-surveys.asp>; 2017 [accessed 14.12.20].